

## Case Report

### Neurolytic erector spinae plane block a treatment for postherpetic neuralgia a case report

Samano-Garcia Marcela<sup>1</sup> and Plancarte-Sanchez Ricardo<sup>1\*</sup>

<sup>1</sup>Pain Medicine Department, National Cancer Institute, Mexico City, Mexico.

#### Abstract

Postherpetic neuralgia (PHN) is the most frequent chronic complication of herpes zoster infection and the most common neuropathic pain resulting from any infection. Many pharmacological treatments and interventional techniques have been used to attempt a good analgesic control. Erector Spine Plane block (ESPB) normally is used with local anesthetic and steroids, and has been successful for short term in PHN cases. We propose the use of lytic ESPB guided by tomography to control PHN in long term. A female of 76 years old with multiple comorbidities and NPH, that presented uncontrolled pain and adverse effects to conventional treatment, interventional management was proposed. A ESPB was performed with local anesthetic and steroid with partial analgesic response for < 4 months. With this scenario a ESPB with phenol guided by Tomography was performed with adequate control pain, reduction of the affected dermatomes and improvement of quality of life that continued for a year with no adverse events reported. Lytic ESPB guided by tomography may be a promising procedure in similar scenarios of non-cancer chronic pain, specially NPH where other therapies fail.

**Keywords:** Neurolytic; Erector SpinaeBlock; postherpetic neuralgia; non-cancer pain.

**Abbreviations:** ESPB: Erector Spine Plane Block; PHN: Postherpetic Neuralgia ; CT: Computed-Tomography ; NRS: Numerical Rating Score; PO: Daily Dose.

#### Introduction

Postherpetic neuralgia (PHN) is the most frequent chronic complication of herpes zoster infection and the most common neuropathic pain resulting from any infection. Between 10-15% of the patients with

Herpes Zoster may develop it [1]. PHN is developed as a result of the damaged peripheral and central nerve fibers due to the virus, resulting in a lower threshold which is traduce give place to central and peripheral sensitization. Patients may experience a variety of abnormal sensations such as allodynia, hyperalgesia, shooting, burning pain, etcetera [2]. Treatment options for PHN include as first line gabapentinoids, antidepressants; and for localized neuropathic pain topical lidocaine patches. As second and third line opioids, topical agents with capsaicin, botulinum toxin; Combination of latter therapies with different mechanisms, have being described [3]. The Interventional techniques for unresponsive pain to conventional therapies also have been described. Most of the interventional techniques for managing PHN, have an evidence Level 2, therefore the recommendation given is B [4]. In this scenario it is clear that novel or different approaches for the treatment of PHN are needed.

Erector Spinae Plane block (ESPB) is an interfascial block that has demonstrated the inhibition of the transmission through spinal nerves and sympathetic nerve fibers, although exact mechanism is not well established. It has been used in neuropathic pain, particularly in PHN with local anesthetics with effective analgesia, in single and repeated doses. The volume needed to cover a specific number of dermatomes is not well established [5, 6]. Tomography may permit the determination of spread in real time [7].

Phenol has proven to be an effective, safe and cheap neurolytic agent. It has been used in refractory non malignant pain with good results and little to non complications [8, 9]. Neurolytic concentration of phenol varies from 3-12%. Phenol has been proposed as an effective alternative in chronic non-malignant pain unresponsive to conventional therapy [10]. We present a case of PHN with refractory pain that went under ESPB with phenol 5% guided by computed tomography (CT).

\*Corresponding Author: Plancarte-Sanchez R, Department of Pain Medicine, National Cancer Institute San Fernando #22, Seccion XVI, Tlalpan, 14080, Mexico City, Mexico, Tel: +52-555-628-0400.

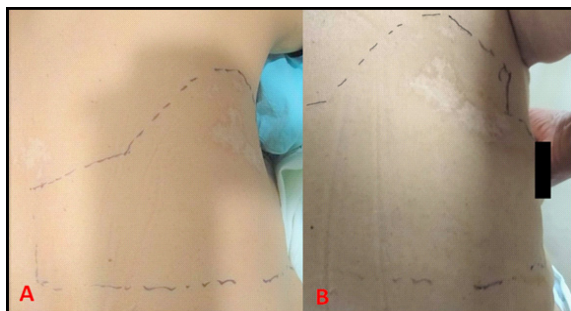
Email: planky@yahoo.com,mx

Received: Feb 18, 2022 Accepted: Mar 06, 2022 Published: Mar 14, 2022

**Citation:** Samano-Garcia Marcela, Plancarte-Sanchez Ricardo. Neurolytic erector spinae plane block a treatment for postherpetic neuralgia a case report. Int Clin Img and Med Rew. 2022; 1(1): 1048.

## Case presentation

A 76 years old female with history of follicular lymphoma treated with chemotherapy and retroperitoneal radiotherapy, under vigilance since April 2017, Diabetes type 2 diagnosed in 2017 in treatment with metformin. Referred to the pain clinic with a severe burning pain in the right thoracic region, which started after Herpes Zoster infections, 4 months before consultation. She also described electric sensation, stabbing, tingling and itching with a constant 9/10 on the numerical rating score (NRS) at T3-T5 dermatomes. Sleep disturbance and impairment in quality of life due to the pain was reported. Physical examination revealed allodynia and hyperesthesia of T2-T7 (**Figure 1**).



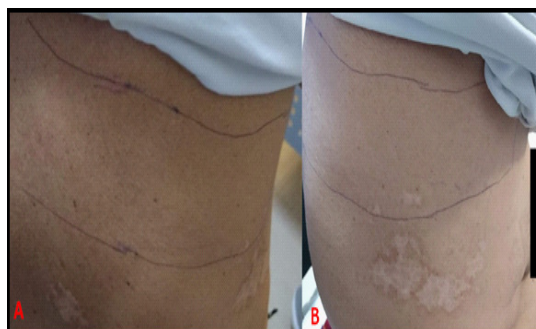**Figure 1:** Delimitation of the affected area by neuropathic alterations before lytic ESPB. A. Posterior Chest view. B Lateral chest view.

Initially managed with pharmacological treatment for 10 months with increasing dose until reaching: pregabalin 150mg/day, amitriptyline 25mg/day and morphine 10mg/day PO, presenting somnolence and dizziness and a 20% of relief in pain intensity. A first ESPB guided by sonography at T5 level in the right side was performed; with bupivacaine 0.25% and methylprednisolone 40 mg with a total volume of 20 ml. An improvement of 50% in intensity describing her pain as moderate and NRS 5/10 persisting neuropathic symptoms and quality of life impairment. Neuromodulator scheme was maintained and the opioid was rotated to tramadol with a dose of 37.5mg/day, the patient did not tolerate higher doses because of adverse effects.

Four months later the pain increased to a severe pain again, NRS 7/10. A CT guided thoracic ESPB at T5 in the right side was performed as follow: Patient was prone positioned, with sterilized skin. A thoracic CT scan was done to localize T5 right transverse process, and marked with the CT laser, skin and subcutaneous tA issue was infiltrated with lidocaine 1%. A 22G block needle was advanced till contact T5 right transverse process, 0.5 ml of contrast was administered and corroborate fascia distribution through CT.

A mix of phenol 10% with contrast was made to obtain phenol 5%, initially 2 ml corroborating distribution by CT scan, with image controls every 4ml with a total volume of 10 ml of phenol 5% of with an extension from T3-T7, as planned. During the follow-up at one week the patient had a 60% of pain relief NRS 3/10 with a low intensity pain reported, persisting pins, itching and hyperalgesia only in T2-T3 dermatome with disappearance of allodynia, burning and electric sensation (**Figure 2**). She decided to discontinue neuromodulators and opioids consumption the day after the procedure. Pain relief persisted in the 2 weeks and one month follow up without any medication. She

also reported better sleeping and quality of life in terms of doing daily activities such as walking, dress, and doing house work without interruption because of pain. In the 6 months and 1 year follow-ups the patient continues with pain relief and improvement in quality of life, no new pains nor adverse effects were reported.



**Figure 2:** Delimitation of the affected area by neuropathic alterations after lytic ESPB. A. Posterior Chest view. B Lateral chest view.

## Discussion

Numerous pharmacological treatments have been used for PHN, but in some cases are ineffective or with several intolerable adverse effects [11]. Specially in these scenarios interventional techniques are useful to relieve pain [4]. ESPB have demonstrated to be effective in neuropathic pain, and specifically in PHN when steroids and local anesthetic are administered [5]. The only inconvenience of this procedure with local anesthetic is the short term pain improvement. In contrast to the long term relief that it can be obtained with phenol injection, even in low doses is achieved, both scenarios showed in our case. We decided to do it with phenol to provide a longer effect and use tomography to determine an adequate spread in real time and cover all the dermatomes we needed, and limit the structures spreaded with phenol. The analgesia achieved was adequate for the patient, who even decided to interrupt pharmacological treatment. She also reported improvement in her quality of life and without adverse effects, even for a year. The results obtained are similar in terms of pain control and no adverse effect to that obtained with lytic ESPB in an oncologic scenario [6, 9]. Is important to comment on the divergence to the postulated by Elkoundi [12], the patient does not have clinical evidence of spinal instability.

## Conclusions

In this case a good long-term analgesia, decrease in the number of neuropathic symptoms and reduction in number of dermatomes involved was obtained. No adverse effect reported nor complication even in the one year follow up. We recommend the smallest concentration of lytic chemical possible and the use of CT to determine the spread of the phenol and prevent complications. More studies should be done to determine the efficacy and security of the lytic ESPB in non-oncological chronic pain with similar scenarios, specially in PHN.

## Conflict of Interest

The authors declare no potential conflicts of interest regarding to the research, authorship and/or publication of this article. Inform consent was obtained for this publication. The authors have no intent to profit financially from this publication.

## References

1. Feller L, Khammissa RAG, Fourie J, Bouckaert M, Lemmer J. Postherpetic Neuralgia and Trigeminal Neuralgia. *Pain Res Treat*. 2017; 2017:1681765.
2. Johnson RW, Rice AS. Postherpetic Neuralgia. *N Engl J Med*. 2014 Oct 16; 371(16):1526-33.
3. Mallick-Searle T, Snodgrass B, Brant JM. Postherpetic neuralgia : epidemiology, pathophysiology, and pain management pharmacology. *J Multidiscip Healthc*. 2016; 9:447-54.
4. Lin CS, Lin YC, Lao HC, Chen CC. Interventional treatments for Postherpetic Neuralgia: A Systematic Review. *Pain Physician*. 2019 may; 22(3):209-28.
5. Ueshima H, Otake H. WITHDRAWN: Erector spinae plane block for pain management of wide post-herpetic neuralgia. *J Clin Anesth*. 2018 Dec; 51:27.
6. Forero M, Adhikary SD, Lopez H, Tsui C, Chin KJ, et al. The Erector Spinae Plane Block: A Novel Analgesic Technique in Thoracic Neuro-pathic Pain. *Reg Anesth Pain Med*. 2016Sep-Oct; 41(5):621-7.
7. Rocha-Romero A, Juarez-Lemus AM, Hernandez-Porras BC. A safer step-by-step approach for erector spinae plane phenol neurolytic blocks. *Can J Anesth*. 2021 Apr; 68(4):585-6.
8. Papa P, Antunez-Maciel M, Asenjo JF. Cancer shoulder pain treated with a neurolytic erector spinae plane block. *Can J Anesth*. 2020 Sep; 67(9):1262-3.
9. Hernandez-Porras BC, Rocha A, Juarez AM. Phenol spread in erector spinae plane block for cancer pain. *Reg Anesth Pain Med*. 2020 Aug; 45(8):671.
10. Weksler N, Klein M, Gurevitch B, Rozentsveig V, Rudich Z, et al. Phenol Neu My-Jun; 8(4):332- 7.
11. Shrestha M, Chen A. Modalities in managing postherpetic neuralgia. *Korean J Pain*. 2018 Oct; 31(4):235-43.
12. Elkoundi A. In reply: A safer step-by-step approach for erector spinae plane phenol neurolytic blocks. *Can J Anesth*. 2021 Apr; 68(4):587-8.